

AMERICAN ACADEMY OF PEDIATRICS

CLINICAL REPORT

Guidance for the Clinician in Rendering Pediatric Care

Jaime L. Frías, MD, Marsha L. Davenport, MD, the Committee on Genetics,
and the Section on Endocrinology

Health Supervision for Children With Turner Syndrome

ABSTRACT. This report is designed to assist the pediatrician in caring for the child in whom the diagnosis of Turner syndrome has been confirmed by karyotyping. The report is meant to serve as a supplement to the American Academy of Pediatrics' "Recommendations for Preventive Pediatric Care" and emphasizes the importance of continuity of care and the need to avoid its fragmentation by ensuring a medical home for every girl with Turner syndrome. The pediatrician's first contact with a child with Turner syndrome may occur during infancy or childhood. This report also discusses interactions with expectant parents who have been given the prenatal diagnosis of Turner syndrome and have been referred for advice.

ABBREVIATIONS. GH, growth hormone; MRI, magnetic resonance imaging; FSH, follicle-stimulating hormone; LH, luteinizing hormone.

INTRODUCTION

Turner syndrome, as used in this report, refers to a condition characterized by short stature and ovarian dysgenesis in females who have a single X chromosome and absence of all or part of the second sex chromosome (X or Y). Nonchromosomal gonadal dysgenesis is excluded. The birth prevalence of Turner syndrome has been estimated to be from 1 in 2000 to 1 in 5000 female live births. Approximately 1% to 2% of all conceptuses have a 45,X chromosome constitution. The majority (99%) of these spontaneously abort, usually during the first trimester of pregnancy. With the more frequent use of ultrasonography, it is recognized that some pregnancies with a fetal 45,X chromosome constitution progressing into the second trimester are associated with nuchal cysts, severe lymphedema, or hydrops fetalis. These pregnancies are associated with a high frequency of fetal death.

PHENOTYPE

Pediatricians are most familiar with the clinical findings that prompt the diagnosis of Turner syn-

drome in children, namely, short stature and other features, such as lymphedema, webbed neck, low posterior hairline, and cubitus valgus. A wide range of clinical abnormalities, including cardiac and renal anomalies, may be found (Table 1). Turner syndrome, however, is not always accompanied by distinctive features and most often is not diagnosed in infancy.¹⁻³ Later in childhood, Turner syndrome may be suspected primarily because of short stature. Other prominent presenting features in teenage years are delayed puberty and delayed menarche, and in adult women, anovulation and infertility.

Growth in children with Turner syndrome is characterized by a slight intrauterine growth restriction, slow growth during infancy and childhood, and lack of a pubertal growth spurt.^{1,2,4,5} Because of delayed epiphyseal closure, small gains in height may occur even after 20 years of age. Average height is rarely achieved, except in girls with mosaicism (the presence in an individual of 2 or more chromosomally different cell lines, both originating from the same zygote) or those whose parents are of above average height. The anticipated adult height is approximately 143 cm and rarely exceeds 150 cm.^{6,7}

Although intelligence is normal, individuals with Turner syndrome are at risk of impairments in the cognitive, behavioral, and social domains. These include learning disabilities, particularly with regard to spatial perception, visual-motor integration, mathematics, memory, the ability to formulate goals and plan action sequences to attain them, and attention span.⁸⁻¹² As a result, the nonverbal IQ in persons with Turner syndrome tends to be lower than the verbal IQ. The behavioral abnormalities differ by age. Younger girls may be hyperactive, immature, and anxious, and anxiety, depression, and unsatisfactory peer relationships are more common in older girls.¹³

A female with 45,X Turner syndrome may manifest an X-linked recessive disorder, such as hemophilia, because she has only 1 X chromosome. Therefore, when an X-linked disorder is identified in a female, the possibility of Turner syndrome caused by monosomy X (absence of an X chromosome: 45,X) or a structural abnormality of an X chromosome should be considered.

The recommendations in this report do not indicate an exclusive course of treatment or serve as a standard of medical care. Variations, taking into account individual circumstances, may be appropriate.

PEDIATRICS (ISSN 0031 4005). Copyright © 2003 by the American Academy of Pediatrics.

TABLE 1. Clinical Abnormalities in Individuals With Turner Syndrome

Very frequent (>50% of individuals)
Growth deficiency
Gonadal dysgenesis
Lymphedema of hands and feet
Deep set, hyperconvex nails
Unusual shape and rotation of ears
Narrow maxilla and dental crowding
Micrognathia
Low posterior hairline
Broad chest with inverted or hypoplastic nipples
Cubitus valgus
Short fourth metacarpals
Tibial exostosis
Tendency to obesity
Recurrent otitis media
Frequent (<50% of individuals)
Hearing loss
Pigmented nevi
Webbed neck
Renal abnormalities
Cardiovascular anomalies
Hypertension
Hypothyroidism
Glucose intolerance
Hyperlipidemia
Occasional (<5% of individuals)
Scoliosis, kyphosis, lordosis
Osteoporosis
Gonadoblastoma
Inflammatory bowel disease
Colon cancer
Neuroblastoma
Juvenile rheumatoid arthritis
Liver disease

CYTOGENETICS

Most characteristics of Turner syndrome appear to result from haploinsufficiency of specific genes on the X chromosome, although abnormal pairing of the sex chromosomes during meiosis is the major factor in oocyte loss and gonadal dysgenesis. Haploinsufficiency refers to the presence in the cell of 1 set of genes rather than the usual 2 sets. In 46,XX female embryos, inactivation of 1 X chromosome, referred to as lyonization, occurs in every somatic cell shortly after fertilization. Some genes involved in Turner syndrome, however, seem to escape inactivation. Thus, the 46,XX female embryo has a functional diploid set of these "pseudoautosomal" genes. These genes also seem to have homologs on the Y chromosome, which accounts for the normal growth and development in XY male embryos.^{14,15}

Current evidence indicates that the genes involved in Turner syndrome are mainly located on the short arm of the X chromosome: Xp11.2-p22.1.¹⁶ A distal homeobox gene (SHOX),* located in the pseudoautosomal region of the X chromosome (PAR1), has been shown to contribute to short stature and some of the skeletal abnormalities observed in individuals with Turner syndrome.¹⁷⁻²⁰ Haploinsufficiency of this gene has been associated with Leri-Weill syndrome, an osteochondrodysplasia characterized by short stature, mesomelic dwarfism, Madelung deformity, and other skeletal abnormalities.^{21,22} Loci con-

*The SHOX or short-stature homeobox-containing gene is also known as PHOG or pseudoautosomal homeobox-containing osteogenic gene.

tributing to normal ovarian function and fetal viability have been identified on the long arm of the X chromosome.²³

In approximately 80% of girls with 45,X Turner syndrome, the single remaining X chromosome is inherited from the mother, and in 20% of these girls, it is inherited from the father.²⁴ Imprinting (an alteration in the expression of a gene or a chromosome, depending on whether the genetic material is inherited from the mother or father) does not seem to operate, because the phenotype of an individual with 45,X Turner syndrome does not vary according to the parental origin of the X chromosome.²⁵ A recent study identified a putative imprinted X-linked gene related to cognitive function, but this has not yet been confirmed.²⁶

When the diagnosis of Turner syndrome is suspected, the appropriate test for confirmation is chromosome analysis. A wide range of karyotypic abnormalities exists within Turner syndrome. When conventional karyotyping is performed using lymphocyte cultures, about 50% of patients show a 45,X chromosome constitution. Another karyotype found with Turner syndrome is mosaicism of 45,X with other cell lines, such as 46,XX, 46,XY, or 47,XXX. Although mosaicism with a 46,XX line (which is the most frequent mosaicism found with 45,X) tends to result in a subtler phenotype on average, the clinical findings cannot be predicted in an individual case. Structural anomalies of an X chromosome, such as isochromosomes (an abnormal chromosome with equal arms originating from a transverse division of the centromere during cell division, instead of the normal longitudinal division), deletions, rings, or translocations, also may be found in a person with Turner syndrome. Structural X anomalies are often mosaic with 45,X or 46,XX cells.

Mosaicism in individuals with Turner syndrome may be more common than was previously thought. When 2 tissues (lymphocytes and fibroblasts) were examined, approximately 80% of patients with 45,X Turner syndrome were found to have mosaicism.²⁷ Mosaicism in live-born girls with Turner syndrome is more common than that in fetuses with Turner syndrome, suggesting that a second sex chromosome (or a critical portion of a second sex chromosome) may be necessary for fetal survival and that most, or perhaps all, individuals with Turner syndrome have mosaicism.^{24,27,28} A Y chromosome is present in 5% to 6% of individuals with Turner syndrome, and an additional 3% have a marker chromosome (a structurally abnormal chromosome that cannot be identified by conventional cytogenetic methods) derived from either the Y or another chromosome.^{29,30}

Girls with 45,X Turner syndrome should have an adequate cytogenetic examination for covert Y chromosome mosaicism, including fluorescence in situ hybridization. Routine use of polymerase chain reaction to identify cryptic Y chromosomal material is not recommended. However, when the karyotype shows a marker chromosome of unknown origin, molecular studies using Y chromosome DNA probes may be helpful in the diagnosis. The possibility of Y chromosome mosaicism also should be investigated

thoroughly if clitoromegaly or masculinized genitalia are present at birth or if virilization occurs at puberty.³¹ When Y chromosome mosaicism is present, there is an increased risk, estimated from 7% to 10%, for developing gonadoblastoma or dysgerminoma in the dysgenetic gonads, and prophylactic gonadectomy is recommended.³²

Buccal smears for X chromatin bodies (Barr bodies) should not be used to screen for or diagnose Turner syndrome. They do not have sufficient sensitivity and specificity, because individuals with mosaicism or a structural X abnormality are often X chromatin positive. Also, a Y chromosome would not be detected in a routine buccal smear that only looks for X chromatin bodies.

MEDICAL TREATMENT

The medical care of children with Turner syndrome requires ongoing assessment and periodic review of specific problems at appropriate ages (Table 2).

Short Stature

Growth hormone (GH) therapy is standard care for a child with Turner syndrome and is usually begun after the child's height falls below the fifth percentile for healthy girls in the same age cohort. More than one half of girls with Turner syndrome will have fallen below the fifth percentile by 2 years of age. For those who experience early growth failure, it appears reasonable to begin GH therapy as early as 2 years of age. A multicenter study of the efficacy and safety of GH initiated at even earlier ages is currently being conducted. Biosynthetic human GH increases the rate of growth in most girls with Turner syndrome without advancing the bone age. Some reports indicate increases in final adult height of 8 to 10 cm if they receive at least 6 years of GH therapy and estrogen production is delayed.^{33,34} Greater height gains have recently been achieved even without delaying estrogen production by initiating GH at an early age and at high doses.³⁵

Cardiovascular Abnormalities

The prevalence of cardiovascular abnormalities among patients with Turner syndrome varies in different series between 20% and 40%.³⁶⁻³⁹ It is higher in patients with monosomy X than in those with structural abnormalities of the X chromosome^{36,37} and in girls with a more pronounced clinical phenotype, such as those with congenital lymphedema and webbed neck, than in those with milder clinical manifestations.^{40,41} Cardiovascular abnormalities typically involve the left side of the heart. Bicuspid aortic valve is the most common malformation, followed by coarctation of the aorta. Other less common but still significant cardiovascular defects in individuals with Turner syndrome are mitral valve prolapse, partial anomalous pulmonary venous drainage, and hypoplastic left heart syndrome. Many of these malformations result in an increased susceptibility to endocarditis, and therefore, prophylactic administration of antibiotics before dental or surgical procedures is essential.⁴²

Aortic root dilatation, present in 3% to 8% of patients with Turner syndrome, may lead to dissecting aneurysm, rupture, and death. Although in most cases aortic dilatation precedes recognized aortic dissection, not all cases end in dissection and not all cases of dissection have antecedent aortic root dilatation. Bicuspid aortic valve, coarctation of the aorta, and systemic hypertension have been identified in approximately 90% of patients with aortic dilatation and dissection.^{38,39,43} These are the same risk factors that are associated with aortic root dilatation in the general population. However, because of the current lack of knowledge about the natural history of aortic dilatation, additional research will be required to identify the best strategy for timely discovery of the problem. In the absence of natural history data, some authorities would advise aortic arch imaging of such patients by echocardiogram or magnetic resonance imaging (MRI) as frequently as every 3 years. Although most instances of aortic dilatation or dissection in individuals with Turner syndrome have been reported among adults, reports of its occurrence in females 21 years or younger^{38,39} raise the possibility that surveillance imaging of the aortic arch for young patients with Turner syndrome could be valuable.

The observation of cystic medial necrosis in individuals with aortic root dilatation has led some to postulate that the aortic abnormality may be caused by a mesenchymal defect. This contention is supported by the evidence of other connective tissue abnormalities, such as those involving the skeletal and lymphatic systems, in patients with Turner syndrome.

On the basis of these considerations, it is recommended that, as part of the initial evaluation, all patients with Turner syndrome have a baseline cardiology evaluation. This may include an echocardiogram, preferably performed at a center experienced in pediatric cardiology, because data indicate that more than one half of echocardiograms performed in children at facilities mostly devoted to adult studies are technically not adequate for interpretation.⁴⁴

The schedule and nature of the cardiology follow-up should be directed by the pediatric cardiologist in concert with the primary care pediatrician and individualized to the patient's needs and the type of defect(s) identified.

Patients with bicuspid aortic valve, aortic stenosis, coarctation of the aorta, or systemic hypertension need close follow-up for aortic dilatation. The cardiologist should decide the periodicity of the evaluations and the method of appraisal (MRI versus echocardiography). Although echocardiography is considered the mainstay of diagnosis, MRI can detect dilatation missed on echocardiography. In addition, MRI should be used when aortic root dilatation is detected to evaluate its severity and provide more precise measurements for follow-up, when findings on echocardiography are equivocal, and when there are technical difficulties because of chest wall configuration or obesity. MRI also can be valuable in assessing the possibility of aortic dissection.⁴⁵⁻⁴⁸

In patients in whom the cardiology evaluation during childhood is normal, the primary care pedi-

TABLE 2. Health Supervision Guidelines for Children With Turner Syndrome*

	Prenatal		Neonatal		Infancy (<1 Year)					Early Childhood (1-5 Years)					Late Childhood (5-13 Years)		Adolescence (13-21 Years)									
			0 Months		2 Months		4 Months		6 Months		9 Months		12 Months		24 Months		3 Years		4 Years		5 Years		Annually		Annually	
At the time of diagnosis																										
Refer to geneticist																										
Refer to endocrinologist																										
Refer to cardiologist																										
Renal sonogram																										
Anticipatory guidance																										
Review family support	TBP		TBP		TBP		TBP		TBP		TBP		TBP		TBP		TBP		TBP		TBP		TBP		TBP	
Stress support groups	TBP		TBP		TBP		TBP		TBP		TBP		TBP		TBP		TBP		TBP		TBP		TBP		TBP	
Long-term planning	TBP		TBP		TBP		TBP		TBP		TBP		TBP		TBP		TBP		TBP		TBP		TBP		TBP	
Medical evaluation																										
Growth failure	TBP		TBP		TBP		TBP		TBP		TBP		TBP		TBP		TBP		TBP		TBP		TBP		TBP	
Hip dysplasia	TBP		TBP		TBP		TBP		TBP		TBP		TBP		TBP		TBP		TBP		TBP		TBP		TBP	
Lymphedema	TBP		TBP		TBP		TBP		TBP		TBP		TBP		TBP		TBP		TBP		TBP		TBP		TBP	
Hypertension/coarctation																										
Hearing loss			O		S		S		O		S		O		S		O		S		O		S		O	
Strabismus			S		S		O		O		O		O		O		O		O		O		O		O	
Malocclusion																										
Thyroid dysfunction																										
Scoliosis or kyphosis																										
Pubertal delay																										
Nevi																										
Psychosocial evaluation																										
Development and behavior																										
School performance																										
Socialization																										
Sexual issues																										

TBP indicates to be performed; S, subjective by history; O, objective by a standard testing method.

* Ensure compliance with the American Academy of Pediatrics Committee on Practice and Ambulatory Medicine. Recommendations for preventive pediatric health care. *Pediatrics*. 2000;105:645.

+ One routine evaluation by specialists during these intervals regardless of history or examination findings: formal audiology, ophthalmology, orthodontic, and psychoeducational examinations.

atrician should pay special attention to the cardiovascular examination, including blood pressure, peripheral pulses, and murmurs. Although there are no evidence-based data regarding the need for a follow-up cardiology evaluation, some have proposed a repeat cardiologic examination during adolescence, ideally performed by a pediatric cardiologist, to look for asymptomatic aortic dilatation.⁴⁶

Primary care pediatricians and pediatric cardiologists need to be aware of the risk of aortic dissection and educate their patients with Turner syndrome about the signs and symptoms of this complication.

Although there has been reassurance that GH does not cause cardiac hypertrophy in girls without cardiac malformation,³⁵ there is inadequate information about its use in girls with underlying aortic stenosis, with or without underlying bicuspid aortic valve.

Hypertension

Up to 40% of girls with Turner syndrome have hypertension,³⁸ and when identified, it should be treated vigorously. Although in most cases hypertension is idiopathic, a careful search for cardiovascular or renal causes should be made.

Hearing Loss

Hearing loss is common in individuals with Turner syndrome. Recurrent otitis media occurs in most girls with Turner syndrome. In addition, a progressive midfrequency sensorineural hearing loss often occurs, which necessitates the use of hearing aids in some children⁴⁹ and more than 25% of women by their mid-forties.⁵⁰

Strabismus

The incidence of strabismus is markedly increased in girls with Turner syndrome, developing in about one third between the ages of 6 months and 7 years.⁵¹ Anterior chamber abnormalities are also more common in girls with Turner syndrome than in those without and may present as congenital glaucoma.

Craniofacial Anomalies

If craniofacial anomalies cause concern, consider plastic surgery for the neck, face, or ears before the child enters school or thereafter, as indicated. Some individuals with Turner syndrome have a tendency to form keloids, which must be taken into account when surgery is considered.^{45,52}

Obesity

Because obesity may be a problem in girls with Turner syndrome, diet and exercise for weight control should be discussed.^{53,54}

Glucose Intolerance

Glucose intolerance occurs more frequently in persons with Turner syndrome than in the general population; however, diabetes mellitus seems to be rare.^{52,55} Monitoring of fasting blood glucose concentrations should be considered in girls who are significantly overweight, have a strong family history of type 2 diabetes mellitus, are Hispanic or African

American, or have signs of insulin resistance, such as acanthosis nigricans.⁵⁶

Urinary Tract Abnormalities

Approximately one third of patients with Turner syndrome have a structural malformation, most commonly horseshoe kidneys, a double collecting system, or abnormal vascular supply. Although most of these malformations do not have clinical significance, they may result in an increased risk of hypertension, urinary tract infections, or hydronephrosis.^{47,57}

Thyroid Dysfunction and Other Autoimmune Disorders

Autoimmune disorders that appear to be more prevalent in individuals with Turner syndrome than the general population include Hashimoto thyroiditis, celiac disease, inflammatory bowel disease, and juvenile rheumatoid arthritis. Individuals with Turner syndrome are at especially high risk of developing hypothyroidism, but this rarely occurs before 4 years of age.⁵⁸

Orthopedic Problems

Congenital developmental dysplasia of the hip occurs more frequently in girls with Turner syndrome than in the general population.^{52,57} This contributes to the development of arthritis of the hips in older individuals. Girls with Turner syndrome also have an increased risk of scoliosis, kyphosis, and lordosis.

Psychosocial Support

The primary care pediatrician should 1) review the psychologic support available to the child and family to optimize the child's psychosocial adjustment; 2) encourage family support by referral to other individuals with Turner syndrome, parents of children with Turner syndrome, or a Turner syndrome support group; and 3) supply the family with literature on Turner syndrome (see Additional Professional Information and Resources for Parents).

THE PRENATAL VISIT

When a prenatal diagnosis of 45,X Turner syndrome or another karyotype associated with Turner syndrome is detected, counseling is ordinarily provided for the family by a medical geneticist, a pediatric endocrinologist, or another physician with special knowledge of Turner syndrome. Sometimes, because of a previous relationship with the family, the pediatrician may be asked to review the information and to assist the family in decision making.

Turner syndrome may be diagnosed or suspected prenatally because of ultrasonographic evidence of fetal edema or nuchal cystic hygroma. Ultrasonography showing a left-sided cardiac defect, renal anomalies, growth retardation, or relatively short limbs also may suggest Turner syndrome. A Turner syndrome karyotype may be discovered fortuitously when fetal chromosome analysis is performed for reasons not associated with an increased incidence of Turner syndrome, such as advanced maternal age. Karyotyping performed when the results of maternal

serum screening with multiple markers (maternal serum α -fetoprotein, human chorionic gonadotropin, and unconjugated estriol) project an increased risk for Down syndrome also has detected some fetuses with Turner syndrome.⁵⁹ If an abnormality associated with Turner syndrome is diagnosed by ultrasonography or if multiple marker screening is positive, the recommended follow-up is fetal karyotyping using amniotic fluid cells obtained by amniocentesis or fetal blood obtained by percutaneous umbilical blood sampling when the karyotype is needed more rapidly.

The spectrum of clinical findings cannot be predicted from the fetal karyotype alone, even in non-mosaic 45,X Turner syndrome. The variability may be increased by mosaicism, which is often not detected in the fetal chromosome analysis. A diagnosis of Turner syndrome made solely by fetal karyotyping should be followed up with careful ultrasonography to define the phenotypic abnormalities as accurately as possible.

Most instances of mosaicism of 45,X and 46,XY diagnosed prenatally have been associated with phenotypically healthy male newborn infants, although the possibility of some clinical abnormality later in life cannot be excluded. If a 45,X or 46,XY fetal karyotype is found, ultrasonographic examination is helpful in diagnosing normal-appearing male genitalia. Determination of amniotic fluid follicle-stimulating hormone (FSH) and testosterone concentrations also may be helpful in confirming the male phenotype.⁶⁰

ANTICIPATORY GUIDANCE

The pediatrician should discuss the diagnosis of Turner syndrome, the phenotype, and the variability of the phenotype. Both parents should be present if possible. They need to know that short stature and infertility are likely, mental retardation is unlikely, some congenital anomalies may be present (Table 1), and some learning difficulties are expected for most but not all individuals. Discuss the treatments and interventions available, such as growth-enhancing therapy and sex hormone replacement, and emphasize that with medical supervision and psychosocial counseling and support, girls with Turner syndrome may lead healthy, satisfying lives. In cases of early prenatal diagnosis, however, some parents may decide to terminate the pregnancy.

Most often, Turner syndrome is a sporadic event, and the risk of recurrence is not increased for subsequent pregnancies. There may be some rare exceptions, however, such as inheritance of a structural X anomaly and inherited mosaicism.⁶¹⁻⁶³

HEALTH SUPERVISION FROM BIRTH TO 1 MONTH OF AGE: NEWBORNS

1. Confirm the diagnosis of Turner syndrome and review the karyotype. If a prenatal diagnosis was made, discuss with the geneticist whether further cytogenetic studies should be performed. Chromosome analyses from peripheral blood or other tissue samples may be indicated, depending on the adequacy of the prenatal study and the possibility of mosaicism, especially for the Y

chromosome. Evaluate the child for typical features of Turner syndrome (Table 1) as follows.

2. Examine the child's hips for dysplasia.⁵² Repeat the examination several times during early infancy.
3. Review results of the newborn hearing screening.
4. Obtain an initial consultation with a cardiologist with experience in pediatric cardiology for all persons with Turner syndrome. This includes patients who had "normal" results on prenatal ultrasonographic examination, because bicuspid aortic valve or coarctation could have been missed.
5. Check blood pressure and peripheral pulses during each physical examination. A careful comparison of arm and leg systolic pressure is important to evaluate for possible coarctation.
6. Perform a renal ultrasound (or repeat the ultrasound if it was done prenatally). If the patient is found to have an abnormality of the urinary tract, continue monitoring for urinary tract infections and renal function.
7. Distinguish the anomalies having major implications on the medical treatment (eg, cardiac and renal anomalies) from those of primarily cosmetic and psychologic importance.
8. Inform the family that lymphedema may persist for months or longer and may recur.
9. Discuss the possibility of feeding problems. Some infants with Turner syndrome have inefficient sucking and swallowing reflexes because of impaired oral motor function.⁶⁴
10. Obtain an initial consultation with a pediatric endocrinologist to discuss the current status of endocrine therapy for growth and for the development of secondary sex characteristics. Indicate that infertility is almost always present, although assisted reproduction techniques may enable infertile women with Turner syndrome to have children.⁶⁵
11. Discuss subacute bacterial endocarditis prophylaxis if a cardiac anomaly is present.
12. Talk about how and what to tell other family members and friends.

HEALTH SUPERVISION FROM 1 MONTH TO 1 YEAR OF AGE: INFANCY

1. Assess the infant's weight, taking into account that many infants with congenital lymphedema lose weight during the first month of life because of diuresis.
2. Check blood pressure and peripheral pulses during each physical examination. A careful comparison of arm and leg systolic pressure is important to evaluate for possible coarctation.
3. Perform an ophthalmologic evaluation. Nonalternating strabismus may be present. Refer the infant to an ophthalmologist as soon as strabismus is suspected.
4. On every visit, check for serous otitis and otitis media and evaluate the child's hearing (objectively at 6 and 12 months of age and before 4 months of age if newborn screening was not

performed). If sensorineural hearing loss is identified, recommend hearing aid evaluation, which can be conducted as early as 3 months of age.^{66,67}

5. If a cardiac anomaly is present, have the patient followed up as frequently as recommended by her cardiologist. Provide prophylaxis for subacute bacterial endocarditis, although subacute bacterial endocarditis is rare in infancy.
6. If urinary tract abnormalities are present, perform a urinalysis and culture when indicated for possible urinary tract infections. Ultrasonography is also advised if urinary tract infections recur or hypertension develops.
7. Consider referring the infant to an appropriate pediatric specialist if renal or eye abnormalities are found.
8. If hypertension is present, treat it aggressively and perform a careful search for cardiovascular or renal causes.
9. Counsel the parents regarding environmental factors that may increase the risk of otitis media, such as bottle feeding, passive smoking, and group child care facility attendance. If otitis media is present, institute aggressive treatment. Discuss the option of tympanostomy tubes for persistent otitis media and consider referral to an otolaryngologist.
10. Refer the infant to developmental intervention programs if neuromuscular development is delayed.

HEALTH SUPERVISION FROM 1 TO 5 YEARS OF AGE: EARLY CHILDHOOD

1. Follow the child's growth and have her evaluated by a pediatric endocrinologist if growth failure occurs. The age at which GH therapy is initiated varies but can be considered at as early as 2 to 3 years of age for girls who are below the fifth percentile for height in the growth chart for healthy girls of the same age. Early initiation of GH therapy may allow for greater gain and normalization of the timing of puberty. Plot growth on the Turner syndrome-specific growth curve starting at 2 years of age (Fig 1).
2. Evaluate the child's speech and refer the child to a speech therapist when appropriate. Consider hearing loss as a possible cause of speech delay.
3. If a cardiac anomaly is present, have the patient followed up as recommended by her cardiologist.
4. Check blood pressure and peripheral pulses during each physical examination. A careful comparison of arm and leg systolic pressure is important to evaluate for possible coarctation.
5. Evaluate the child's hearing and check for serous otitis and otitis media during every visit.
6. Continue to evaluate the child's renal status (urinalysis and culture, as indicated) if a renal anomaly is present.
7. Test for thyroid function by measuring thyroid-stimulating hormone and free or total thyroxine levels at 1- to 2-year intervals because of the increased frequency of hypothyroidism usually caused by autoimmune thyroiditis. In the ab-

sence of clinical signs, initiation of thyroid function testing may be delayed until after 4 years of age or later, because hypothyroidism is rare before then.⁴⁷

8. Evaluate the child for possible developmental delay and learning difficulties, particularly spatial perception problems. An assessment of the child before entering a preschool program may benefit the child and parents as well as school personnel. Information about testing and evaluation resources may be obtained from the school or from state and regional programs for persons with developmental disabilities.
9. If hypertension is present, treat it aggressively and perform a careful search for cardiovascular or renal causes.
10. Counsel the parents regarding environmental factors that may increase the risk of otitis media, such as bottle feeding, passive smoking, and group child-care facility attendance. If otitis media is present, institute aggressive treatment. Discuss the option of tympanostomy tubes for persistent otitis media and consider referral to an otolaryngologist.

HEALTH SUPERVISION FROM 5 TO 13 YEARS OF AGE: LATE CHILDHOOD

1. Discuss the diagnosis and treatment of Turner syndrome with the child as soon as she is able to understand as well as with the parents.
2. Continue to monitor growth carefully. In addition to GH, the endocrinologist may consider adding oxandrolone to the GH treatment regimen in older girls (9–12 years of age) with extreme short stature or those in whom the response to GH is not adequate.³³
3. Monitor the child for urinary tract infections if urinary tract abnormalities are present.
4. Check blood pressure and peripheral pulses during each physical examination. A careful comparison of arm and leg systolic pressure is important to evaluate for possible coarctation.
5. Evaluate the child's hearing and check for serous otitis and otitis media during every visit. Advise patients to protect their hearing by avoiding loud noises.
6. Check the child's dentition for malocclusion.
7. Continue testing for thyroid function at 1- or 2-year intervals.
8. Check for scoliosis yearly. Lordosis and kyphosis are also seen more frequently in girls with, than in girls without, Turner syndrome.
9. Watch for potential school problems, such as specific learning disabilities, attention deficits, hyperactivity, and difficulty in developing social skills. Refer the child for educational evaluation and intervention, as indicated. Encourage parents to interact with school personnel.
10. Discuss adjustment to short stature with the parents and separately with the child.
11. If hypertension is present, treat it aggressively and perform a careful search for cardiovascular or renal causes.

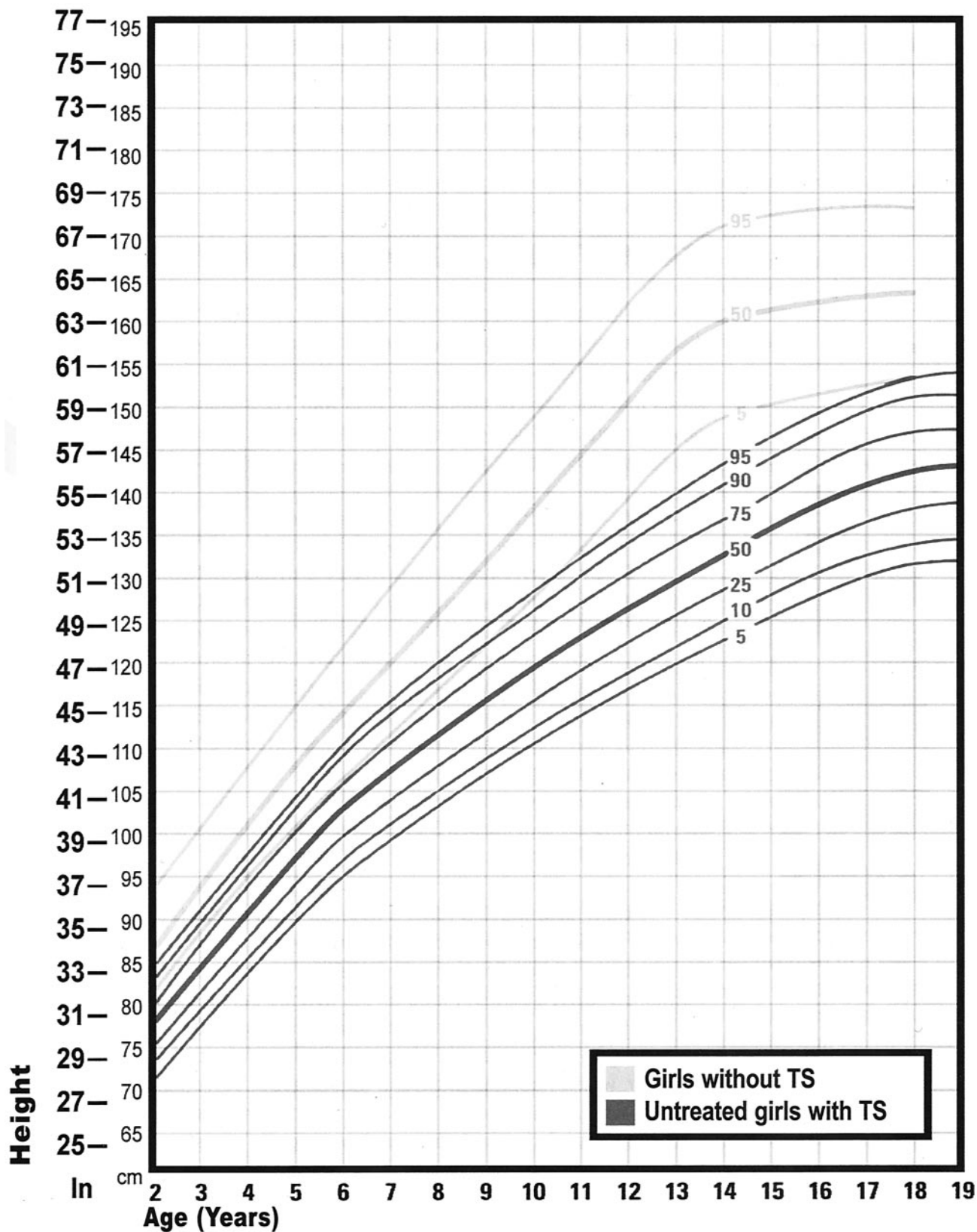


Fig 1. Growth chart for children with Turner syndrome. Source: Rieser P, Davenport M. *Turner Syndrome: A Guide for Families*. Houston, TX: Turner Syndrome Society of the United States; 2002. Data derived from Lyon et al.⁷

12. If otitis media is present, institute aggressive treatment. Discuss the option of tympanostomy tubes for persistent otitis media and consider referral to an otolaryngologist. Advise patients to protect their hearing by avoiding loud noises.
13. Counsel the family regarding the importance of optimizing bone density, and advise that the patient receive the recommended daily requirements for Vitamin D and calcium through diet or supplementation.

HEALTH SUPERVISION FROM 13 TO 21 YEARS OR OLDER: ADOLESCENCE TO EARLY ADULTHOOD

1. Examine the adolescent for pigmented nevi, which may not be prominent in young children but tend to increase in frequency in adolescence and older ages. Pigmented nevi have primarily cosmetic significance. Advise removal of the nevi if they are rubbed by clothing. The risk of melanoma, which is low, does not appear to be increased by GH treatment.^{68,69}
2. Check blood pressure and peripheral pulses during each physical examination. A careful comparison of arm and leg systolic pressure is important to evaluate for possible coarctation.
3. Measure fasting lipid profile at least once during adolescence to screen for hyperlipidemia, especially in those who have a positive family history, have diabetes mellitus, or are overweight.
4. Evaluate the child's hearing and check for serous otitis and otitis media during every visit. If otitis media is present, institute aggressive treatment. Advise patients to protect their hearing by avoiding loud noises.
5. Check the adolescent annually for scoliosis and kyphosis.
6. Even for individuals with normal initial cardiac evaluation, refer to a cardiologist for a complete evaluation, including a close evaluation of the aortic root.
7. Continue to test the adolescent's thyroid function every 1 to 2 years.
8. Evaluate the adolescent for development of secondary sex characteristics. As many as one third of girls with mosaicism will enter puberty spontaneously. Measurement of luteinizing hormone (LH) and FSH concentrations may be helpful in assessing gonadal function.⁷⁰ Increased LH and FSH concentrations will help to confirm that the child is physiologically ready for initiation of estrogen therapy, and evidence of suppression of LH and FSH into the normal range may help to determine adequacy of the maintenance dose chosen.
9. Refer the adolescent to a pediatric endocrinologist for evaluation of sex hormone replacement. If gonadotropin levels are increased, initiate estrogen therapy and then begin cyclic therapy with a progestin at an appropriate age. Estrogen therapy may be initiated as early as 12 years of age for girls who are satisfied with their height. For others, estrogen therapy can be delayed until as late as 15 years of age to maximize height. Individualize treatment choices concerning the timing of feminizing therapy and length of growth enhancing therapy to the patient's psychosocial needs.
10. If hypertension is present, treat it aggressively and perform a careful search for cardiovascular or renal causes.
11. If otitis media is present, institute aggressive treatment.
12. If lymphedema is exacerbated by estrogen ther-

apy, combined decongestive therapy that uses manual lymphatic drainage, low-stretch support garments, and exercises may be effective.⁷¹ Some physicians also use diuretics.

13. Continue to monitor school function and behavior.
14. Discuss social adaptation. Girls with Turner syndrome tend to be socially immature for their age and need support in developing independence and social interactions. Support groups of girls with Turner syndrome are especially helpful. Provide psychosexual counseling.
15. Present information on reproductive options to bearing children, such as adoption and medically assisted reproduction.
16. Provide counseling regarding sexuality and sexually transmitted diseases.
17. Refer the rare girl with Turner syndrome who has sufficient ovarian function to ovulate and who may become pregnant for genetic counseling and prenatal diagnosis (if pregnant). These girls are at increased risk of having a fetus with chromosome abnormalities and having miscarriages.⁷² Offer contraception advice when appropriate.
18. Facilitate transfer of the adolescent to adult medical care.

COMMITTEE ON GENETICS, 2002–2003
Christopher Cunniff, MD, Chairperson
Joseph H. Hersh, MD
H. Eugene Hoyme, MD
Celia I. Kaye, MD, PhD
John B. Moeschler, MD
G. Bradley Schaefer, MD
Tracy L. Trotter, MD

Jaime L. Frías, MD
Past Committee Member

LIAISONS
James W. Hanson, MD
American College of Medical Genetics
Michele Lloyd-Puryear, MD, PhD
Health Resources and Services Administration
Cynthia A. Moore, MD, PhD
Centers for Disease Control and Prevention
Lee P. Shulman, MD
American College of Obstetricians and Gynecologists

CONSULTANT
David Danford, MD

STAFF
Paul Spire

SECTION ON ENDOCRINOLOGY, 2002–2003
Janet Silverstein, MD, Chairperson
Kenneth Copeland, MD
Inger L. Hansen, MD
Francine Kaufman, MD
Susan R. Rose, MD
Surendra Kumar Varma, MD

Marsha L. Davenport, MD
Section Member

LIAISON
Lynne L. Levitsky, MD
Lawson Wilkins Pediatric Endocrinology Society

REFERENCES

- Massa GG, Vanderschueren-Lodeweyckx M. Age and height at diagnosis in Turner syndrome: influencer of parental height. *Pediatrics*. 1991;88:1148–1152
- Cunniff C, Hased SJ, Hendon AE, Rickert VI. Health care utilization and perceptions of health among adolescents and adults with Turner syndrome. *Clin Genet*. 1995;48:17–22
- Savendahl L, Davenport ML. Delayed diagnoses of Turner's syndrome: proposed guidelines for change. *J Pediatr*. 2000;137:455–459
- Davenport ML, Punyasavatsut N, Gunther D, Savendahl L, Stewart PW. Turner syndrome: a pattern of early growth failure. *Acta Paediatr Suppl*. 1999;433:118–121
- Even L, Cohen A, Marbach N, et al. Longitudinal analysis of growth over the first 3 years of life in Turner's syndrome. *J Pediatr*. 2000;137:460–464
- Ranke MB, Pfluger H, Rosendahl W, et al. Turner syndrome: spontaneous growth in 150 cases and review of the literature. *Eur J Pediatr*. 1983;141:81–88
- Lyon AJ, Preece MA, Grant DB. Growth curve for girls with Turner syndrome. *Arch Dis Child*. 1985;60:932–935
- Robinson A, Bender BG, Linden MG, Salbenblatt JA. Sex chromosome aneuploidy: the Denver Prospective Study. *Birth Defects Orig Artic Ser*. 1990;26:59–115
- Rovet JF. The psychoeducational characteristics of children with Turner syndrome. *J Learn Disabil*. 1993;26:333–341
- Siegel PT, Clopper R, Stabler B. The psychological consequences of Turner syndrome and review of the National Cooperative Growth Study Psychological Substudy. *Pediatrics*. 1998;102:488–491
- Ross JL, Roeltgen D, Kushner H, Wei F, Zinn AP. The Turner syndrome-associated neurocognitive phenotype maps to distal Xp. *Am J Hum Genet*. 2000;67:672–681
- Mazzocco MM. A process approach to describing mathematics difficulties in girls with Turner syndrome. *Pediatrics*. 1998;102:492–496
- McCauley E, Ross J, Sybert V. Self-concept and behavioral profiles in females with Turner syndrome. In: Stabler B, Underwood LE, eds. *Growth, Stature, and Adaptation: Behavioral, Social, and Cognitive Aspects of Growth Delay*. Chapel Hill, NC: University of North Carolina; 1994:181–194
- Ferguson-Smith MA. Karyotype-phenotype correlations in gonadal dysgenesis and their bearing on the pathogenesis of malformations. *J Med Genet*. 1965;2:142–155
- Lahn BT, Page DC. Functional coherence of the human Y chromosome. *Science*. 1997;278:675–680
- Zinn AR, Tonk VS, Chen Z, et al. Evidence for a Turner syndrome locus or loci at Xp11.2-p22.1. *Am J Hum Genet*. 1998;63:1757–1766
- Rao E, Weiss B, Fukami M, et al. Pseudoautosomal deletions encompassing a novel homeobox gene cause growth failure in idiopathic short stature and Turner syndrome. *Nat Genet*. 1997;16:54–63
- Ellison JW, Wardack Z, Young MF, Gehron Robey P, Laig-Webster M, Chiong W. PHOG, a candidate gene for involvement in the short stature of Turner syndrome. *Hum Mol Genet*. 1997;6:1341–1347
- Clement-Jones M, Schiller S, Rao E, et al. The short stature homeobox gene SHOX is involved in skeletal abnormalities in Turner syndrome. *Hum Mol Genet*. 2000;9:695–702
- Kosho T, Muroya K, Nagai T, et al. Skeletal features and growth patterns in 14 patients with haploinsufficiency of SHOX: implications for the development of Turner syndrome. *J Clin Endocrinol Metabol*. 1999;84:4613–4621
- Belin V, Cusin V, Viot G, et al. SHOX mutations in dyschondrosteosis (Leri-Weill syndrome). *Nat Genet*. 1998;19:67–69
- Shears DJ, Vassal HJ, Goodman FR, et al. Mutation and deletion of the pseudoautosomal gene SHOX cause Leri-Weill dyschondrosteosis. *Nat Genet*. 1998;19:70–73
- Zinn AR, Page DC, Fisher EM. Turner syndrome: the case of the missing sex chromosome. *Trends Genet*. 1993;9:90–93
- Hassold T, Benham F, Leppert M. Cytogenetic and molecular analysis of sex-chromosome monosomy. *Am J Hum Genet*. 1988;42:534–541
- Mathur A, Stekol L, Schatz D, MacLaren NK, Scott ML, Lippe B. The parental origin of the single X chromosome in Turner syndrome: lack of correlation with parental age or clinical phenotype. *Am J Hum Genet*. 1991;48:682–686
- Skuse DH, James RS, Bishop DV, et al. Evidence from Turner's syndrome of an imprinted X-linked locus affecting cognitive function. *Nature*. 1997;387:705–708
- Held KR, Kerber S, Kaminsky E, et al. Mosaicism in 45, X Turner syndrome: does survival in early pregnancy depend on the presence of two sex chromosomes? *Hum Genet*. 1992;88:288–294
- Hook EB, Warburton D. The distribution of chromosomal genotypes associated with Turner's syndrome: livebirth prevalence rates and evidence for diminished fetal mortality and severity in genotypes associated with structural X abnormalities or mosaicism. *Hum Genet*. 1983;64:24–27
- Patsalis PC, Hadjimarkou MI, Velissariou V, et al. Supernumerary marker chromosomes (SMCs) in Turner syndrome are mostly derived from the Y chromosome. *Clin Genet*. 1997;51:184–190
- Chu CE, Connor JM, Donaldson MD, Kelnar CJ, Smail PJ, Greene SA. Detection of Y mosaicism in patients with Turner's syndrome. *J Med Genet*. 1995;32:578–580
- Zinn AR, Page DC. Turner syndrome and the Y chromosome. In: Hibi I, Takano K, eds. *Basic and Clinical Approach to Turner Syndrome: Proceedings of the 3rd International Symposium on Turner Syndrome, Chiba, Japan, July 8–10, 1992*. New York, NY: Elsevier Science; 1993:49–56
- Gravholt CH, Fedder J, Naeraa RW, Muller J. Occurrence of gonadoblastoma in females with Turner syndrome and Y chromosomal material: a population study. *J Clin Endocrinol Metab*. 2000;85:3199–3202
- Rosenfeld RG, Attie KM, Frane J, et al. Growth hormone therapy of Turner's syndrome: beneficial effect on adult height. *J Pediatr*. 1998;132:319–324
- Saenger P. Growth-promoting strategies in Turner's syndrome. *J Clin Endocrinol Metab*. 1999;84:4345–4348
- Sas TC, de Muinck Keizer-Schrama SM, Stijnen T, et al. Normalization of height in girls with Turner syndrome after long-term growth hormone treatment: results of a randomized dose-response trial. *J Clin Endocrinol Metab*. 1999;84:4607–4612
- Gotzsche CO, Krag-Olsen B, Nielsen J, Sorensen KE, Kristensen BO. Prevalence of cardiovascular malformations and association with karyotypes in Turner's syndrome. *Arch Dis Child*. 1994;71:433–436
- Mazzanti L, Cacciari E. Congenital heart disease in patients with Turner's syndrome. Italian Study Group for Turner Syndrome (ISGTS). *J Pediatr*. 1998;133:688–692
- Sybert VP. Cardiovascular malformations and complications in Turner syndrome. *Pediatrics*. 1998;101(1). Available at: <http://www.pediatrics.org/cgi/content/full/101/1/e11>
- Lin AE, Lippe B, Rosenfeld RG. Further delineation of aortic dilatation, dissection, and rupture in patients with Turner syndrome. *Pediatrics*. 1998;102(1). Available at: <http://www.pediatrics.org/cgi/content/full/102/1/e12>
- Clark EB. Neck web and congenital heart defects: a pathogenic association in 45 X-O Turner syndrome? *Teratology*. 1984;29:355–361
- Lacro RV, Jones KL, Benirschke K. Coarctation of the aorta in Turner syndrome: a pathologic study of fetuses with nuchal cystic hygromas, hydrops fetalis, and female genitalia. *Pediatrics*. 1988;81:445–551
- Dajani AS, Taubert KA, Wilson W, et al. Prevention of bacterial endocarditis. Recommendations by the American Heart Association. *Circulation*. 1997;96:358–366
- Bordeleau L, Cwinn A, Turek M, Barron-Klauninger K, Victor G. Aortic dilatation and Turner's syndrome: case report and review of the literature. *J Emerg Med*. 1998;16:593–596
- Hurwitz RA, Caldwell RL. Should pediatric electrocardiography be performed in adult laboratories? *Pediatrics*. 1998;102(2). Available at: <http://www.pediatrics.org/cgi/content/full/102/2/e15>
- Dawson-Falk KL, Wright AM, Bakker B, Pitlick PT, Wilson DM, Rosenfeld RG. Cardiovascular evaluation in Turner syndrome: utility of MR imaging. *Australas Radiol*. 1992;36:204–209
- Lin AE. Management of cardiac problems. In: Saenger P, Pasquino AM, eds. *Optimizing Health Care for Turner Patients in the 21st Century: Proceedings of the 5th International Symposium on Turner Syndrome, Naples, Italy, March 23–25, 2000*. New York, NY: Elsevier Science; 2000:115–123
- Elsheikh M, Conway GS, Wass JA. Medical problems in adult women with Turner's syndrome. *Ann Med*. 1999;31:99–105
- Saenger P. Turner's syndrome. *N Engl J Med*. 1996;335:1749–1754
- Stenberg AE, Nylén O, Windh M, Hultcrantz M. Otological problems in children with Turner's syndrome. *Hear Res*. 1998;124:85–90
- Hultcrantz M, Sylven L, Borg E. Ear and hearing problems in 44 middle-aged women with Turner's syndrome. *Hear Res*. 1994;76:127–132
- Chrousos GA, Ross JL, Chrousos GC, et al. Ocular findings in Turner syndrome: a prospective study. *Ophthalmology*. 1984;91:926–928
- Hall JG. The management of the adult with Turner syndrome: the natural history of Turner syndrome. In: Rosenfeld RG, Grumbach MM, eds. *Turner Syndrome*. New York, NY: Marcel Dekker Inc; 1989:495–506
- Elsheikh M, Conway GS. The impact of obesity on cardiovascular risk factors in Turner's syndrome. *Clin Endocrinol (Oxf)*. 1998;49:447–450

54. Ross JL, Feullian P, Long LM, Kowal K, Kushner H, Cutler GB Jr. Lipid abnormalities in Turner syndrome. *J Pediatr*. 1995;126:242–245
55. Lippe B. Turner syndrome. *Endocrinol Metab Clin North Am*. 1991;20:121–152
56. American Diabetes Association. American Diabetes Association: clinical practice recommendations 2000. *Diabetes Care*. 2000;23(suppl 1):S1–S116
57. Saenger P, Albertsson-Wikland K, Conway GS, et al. Fifth International Symposium on Turner Syndrome. Recommendations for the diagnosis and management of Turner syndrome. *J Clin Endocrinol Metab*. 2001;86:3061–3069
58. Medeiros CC, Marini SH, Baptista MT, Guerra G Jr, Maciel-Guerra AT. Turner's syndrome and thyroid disease: a transverse study of pediatric patients in Brazil. *J Pediatr Endocrinol Metab*. 2000;13:357–362
59. Wenstrom KD, Williamson RA, Grant SS. Detection of fetal Turner syndrome with multiple-marker screening. *Am J Obstet Gynecol*. 1994;170:570–573
60. Koeberl DD, McGillivray B, Sybert VP. Prenatal diagnosis of 45, X/46, XX mosaicism and 45, X: implications for postnatal outcome. *Am J Hum Genet*. 1995;57:661–666
61. Verschraegen-Spae MR, Depypere H, Speleman F, Dhondt M, De Paepe A. Familial Turner syndrome. *Clin Genet*. 1992;41:218–220
62. Kher AS, Chattopadhyay A, Datta S, Kanade S, Sreenivasan VK, Barucha BA. Familial mosaic Turner syndrome. *Clin Genet*. 1994;46:382–383
63. Aller V, Gargallo M, Abrisqueta JA. Familial transmission of a duplication-deficiency X chromosome associated with partial Turner syndrome. *Clin Genet*. 1995;48:317–320
64. Mathisen B, Reilly S, Skuse D. Oral-motor dysfunction and feeding disorders of infants with Turner syndrome. *Dev Med Child Neurol*. 1992;34:141–149
65. Hovatta O. Pregnancies in women with Turner's syndrome. *Ann Med*. 1999;31:106–110
66. Barrenasa M, Landin-Wilhelmsen K, Hansson C. Ear and hearing in relation to genotype and growth in Turner syndrome. *Hear Res*. 2000;144:21–28
67. Roush J, Davenport ML, Carlson-Smith C. Early-onset sensorineural hearing loss in a child with Turner syndrome. *J Am Acad Audiol*. 2000;11:446–453
68. Gare M, Ilan Y, Sherman Y, Ben-Chetrit E. Malignant melanoma in Turner's syndrome. *Int J Dermatol*. 1993;32:743–744
69. Wyatt D. Melanocytic nevi in children treated with growth hormone. *Pediatrics*. 1999;104:1045–1050
70. Pasquino AM, Passeri F, Pucarelli I, Segni M, Municchi G. Spontaneous pubertal development in Turner's syndrome. Italian Study Group for Turner's Syndrome. *J Clin Endocrinol Metab*. 1997;82:1810–1813
71. Lerner R. What's new in lymphedema therapy in America? *Int J Angiology*. 1998;7:191–196
72. Tarani L, Lampariello S, Raguso G, et al. Pregnancy in patients with Turner's syndrome: six new cases and review of literature. *Gynecol Endocrinol*. 1998;12:83–87

ADDITIONAL PROFESSIONAL INFORMATION

- Saenger P, Pasquino AM, eds. *Optimizing Health Care for Turner Patients in the 21st Century: Proceedings of the 5th International Symposium on Turner Syndrome, Naples, Italy, March 23–25, 2000*. New York, NY: Elsevier Science; 2000
- Rosenfeld RG, Grumbach MM, eds. *Turner Syndrome*. New York, NY: Marcel Dekker; 1989
- Turner Syndrome. A Comprehensive Guide* (free CD-ROM from Eli Lilly). Available at: <http://www.lillycme.com/actvts.htm>

RESOURCES FOR PARENTS

- Turner Syndrome Society of the United States*
 14450 TC Jester, Suite 260, Houston, TX 77014
 Toll-free: 800-365-9944
 Local: 832-249-9988
 Fax: 832-249-9987
 Internet: <http://www.turner-syndrome-us.org>
- National Institute of Child Health and Human Development*
 Internet: <http://turners.nichd.nih.gov>

All clinical reports from the American Academy of Pediatrics automatically expire 5 years after publication unless reaffirmed, revised, or retired at or before that time.